

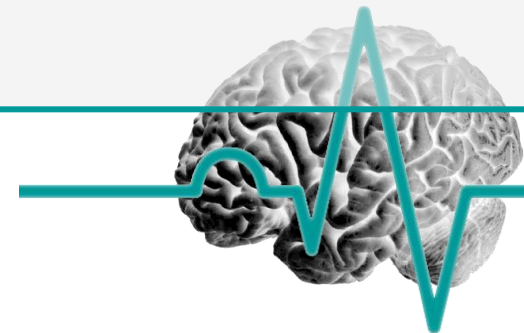# INFECTIOUS COMPLICATIONS IN THE NEURO-ICU

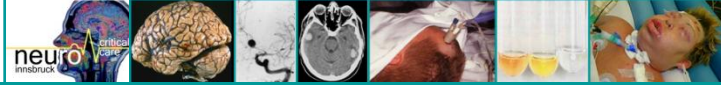
**Erich Schmutzhard**

**Department of Neurology, NICU**

**Medical University Hospital**

**A-6020 Innsbruck, Austria**



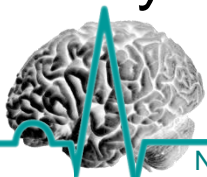

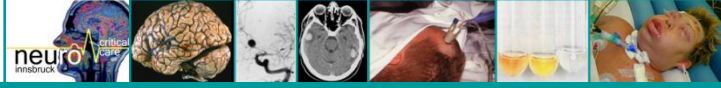
## NEUROCRITICAL CARE COMPLICATIONS IN THE ICU

Infectious complications in the neuro-ICU patient population presenting as

- meningitis,**
- ventriculitis,**
- encephalitis/cerebritis,**
- brain abscess,** and
- subdural or epidural empyema**

are frequently associated with **invasive** procedures such as **craniotomy** or placement of **intracranial devices** necessary, for example, for intracranial pressure (ICP) monitoring or diversion of the cerebrospinal fluid (CSF) from an obstructed ventricular system.



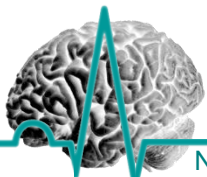


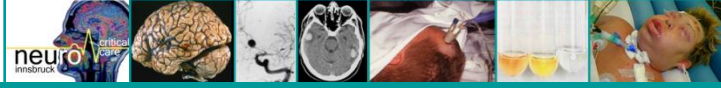
## NEUROCRITICAL CARE COMPLICATIONS IN THE ICU

The majority of these infections must be considered **nosocomial**, that is, hospital-acquired.

Recently, the term nosocomial has been suggested to be replaced by **healthcare-associated** (Lujan et al 2009).

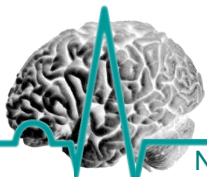

This concept may be highly useful for the categorization of infections in the **non-ICU** setting, but seems to be **less** applicable in the **neuro-ICU** patient population.

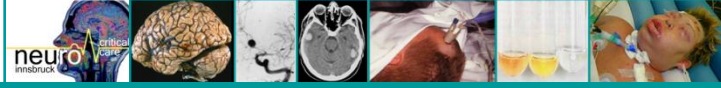




## NEUROCRITICAL CARE COMPLICATIONS IN THE ICU

Due to the severity of the underlying neurological illness such as aneurysmal subarachnoid hemorrhage or severe traumatic brain injury, neurocritical care patients often require the full range of ICU measures including mechanical ventilation, intravascular catheters, and so on.

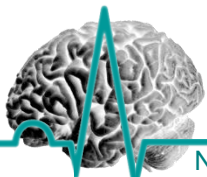


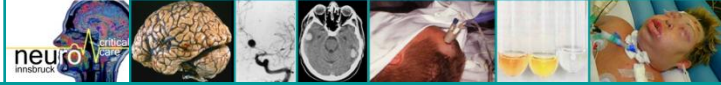


## NEUROCRITICAL CARE COMPLICATIONS IN THE ICU

Therefore, these patients are also at high risk for infections arising at distant foci, e.g.,

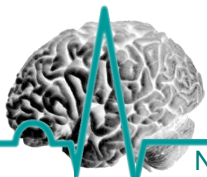
- endocarditis,
- bloodstream infections,
- pneumonia,
- urinary tract infections
- colitis, etc

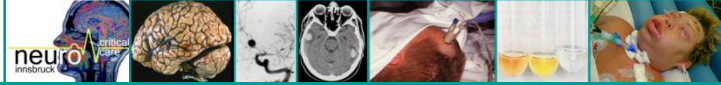




## NEUROCRITICAL CARE COMPLICATIONS IN THE ICU

Noteworthy, a neuro-ICU patient suffering from sepsis originating from an extracranial focus is at risk for **sepsis-related neurological complications** like  
-**septic encephalopathy** or  
-**critical illness neuromyopathy**.

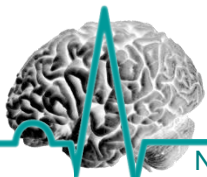





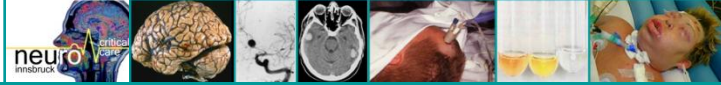
## NEUROCRITICAL CARE COMPLICATIONS IN THE ICU

In addition, infectious complications may arise from more 'exogenous' sources such as transmission of pathogens from ICU personnel or the ICU environment.

**Poor hand hygiene** has been demonstrated to be one of the most important causes of healthcare-associated infections.





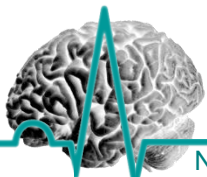


## NEUROCRITICAL CARE COMPLICATIONS IN THE ICU

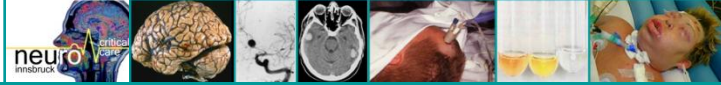
### Definition of intracranial infectious complications

Recently, the **N**ational **H**ealthcare **S**afety **N**etwork, Division of Healthcare Quality Promotion of the Centers for Disease Control and Prevention (CDC/**NHSN**) has updated the surveillance definition of healthcare-associated infection and published criteria for various types of infections in the acute care setting.

(Horan et al 2008)







## NEUROCRITICAL CARE COMPLICATIONS IN THE ICU

**There are three specific types of central nervous system (CNS) infections:**

(1) Intracranial infection:

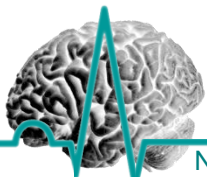

a) brain abscess

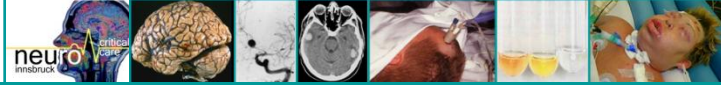
b) subdural or epidural infection, and

c) encephalitis

(2) Meningitis or ventriculitis

(3) Spinal abscess without meningitis

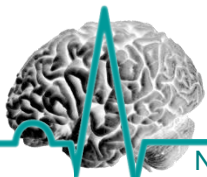


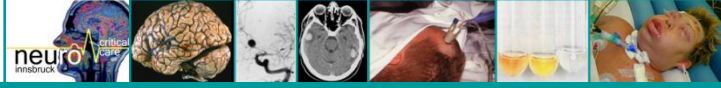


## NEUROCRITICAL CARE COMPLICATIONS IN THE ICU

As per the CDC/NHSN definition of **CNS infection**, **intracranial infection** must meet at least one of the following criteria:

- 1) Patient has organisms **cultured** from **brain** tissue or **dura**
- 2) Patient has an **abscess** or evidence of **intracranial infection** seen **during a surgical** operation or on **histopathologic** examination.



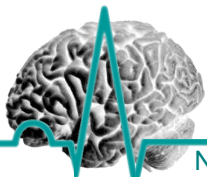


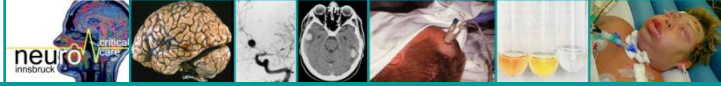
## NEUROCRITICAL CARE COMPLICATIONS IN THE ICU

3) Patient has at least two of the following signs or symptoms with no other recognized cause:

- headache**,
- dizziness**,
- fever (>38.8C)**,
- localizing neurologic signs**,
- changing level of consciousness**, or
- confusion**,

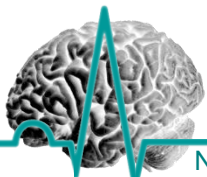
**and** at least one of the following:

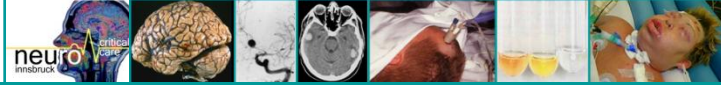




## NEUROCRITICAL CARE COMPLICATIONS IN THE ICU

- (a) organisms seen on microscopic examination of brain or abscess tissue obtained by **needle aspiration** or by **biopsy** during a surgical operation or autopsy,
- (b) positive antigen test on blood or urine,
- (c) **radiographic** evidence of infection, and
- (d) diagnostic single antibody titer (IgM) or four-fold increase in paired sera (IgG) for pathogen;
- (e) and if diagnosis is made ante-mortem, physician institutes appropriate antimicrobial therapy.



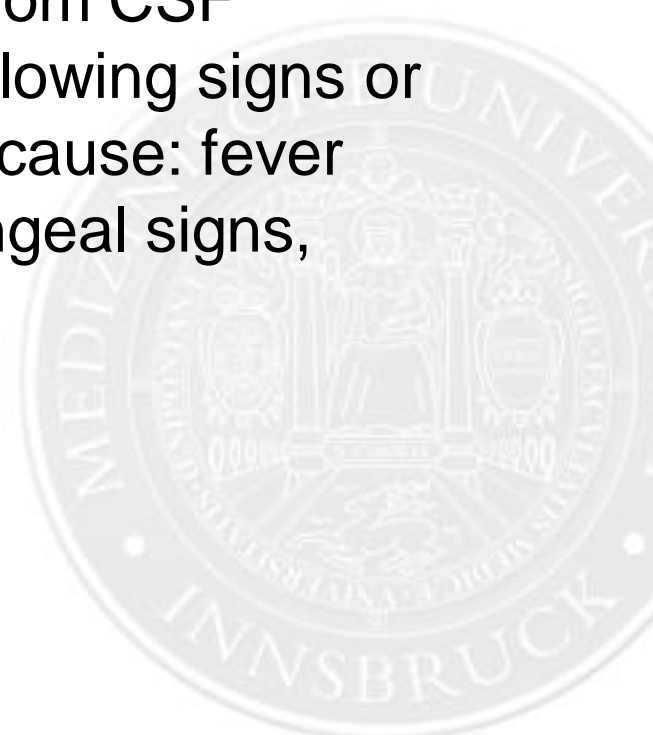
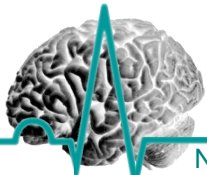


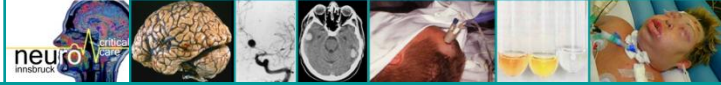
## NEUROCRITICAL CARE COMPLICATIONS IN THE ICU

As per the CDC/NHSN definition of **meningitis** or **ventriculitis**, at least one of the following criteria must be met:

- (1) Patient has organisms cultured from CSF
- (2) Patient has at least one of the following signs or symptoms with no other recognized cause: fever ( $>38^{\circ}\text{C}$ ), headache, stiff neck, meningeal signs, cranial nerve signs, or irritability

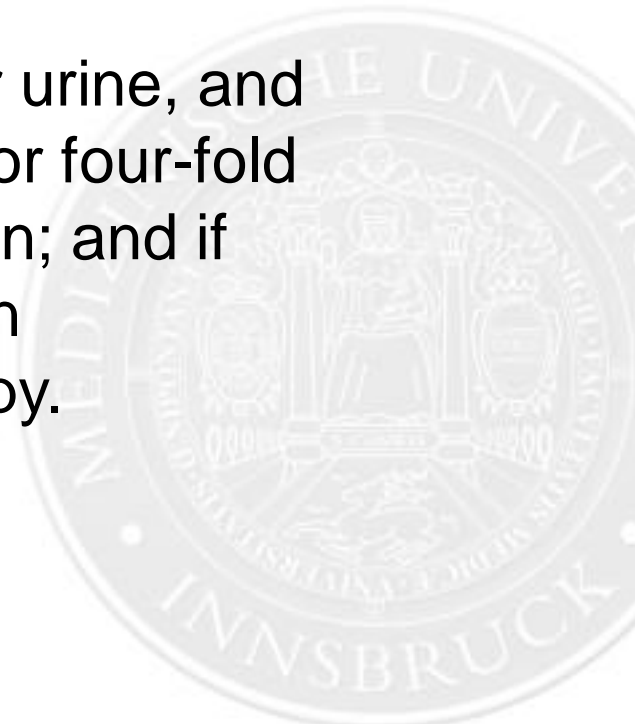
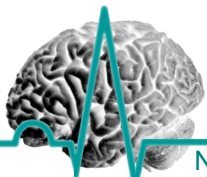
and at least one of the following:

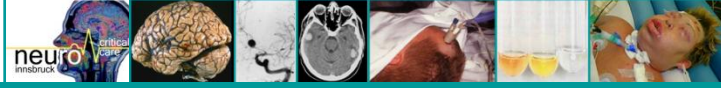




## NEUROCRITICAL CARE COMPLICATIONS IN THE ICU

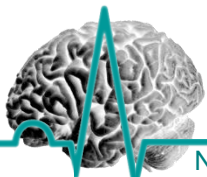
- (a) increased white cells, elevated protein, and/or decreased glucose in CSF,
- (b) organisms seen on Gram's stain of CSF,
- (c) organisms cultured from blood,
- (d) positive antigen test of CSF, blood, or urine, and
- (e) diagnostic single antibody titer (IgM) or four-fold increase in paired sera (IgG) for pathogen; and if diagnosis is made antemortem, physician institutes appropriate antimicrobial therapy.



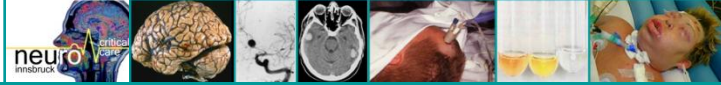


## NEUROCRITICAL CARE COMPLICATIONS IN THE ICU

In addition to these major types, other intracranial infections may arise in the neuro-ICU patient population such as -septic thrombosis of cerebral sinus and/or -veins.







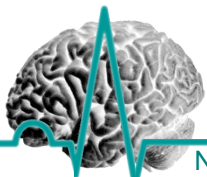
## NEUROCRITICAL CARE COMPLICATIONS IN THE ICU

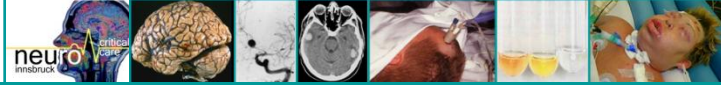
### **Infection** versus **contamination** and catheter **colonization**

Infections that require immediate therapeutic attention must be differentiated from contamination and catheter colonization.

**Contamination** constitutes an isolated positive CSF culture in the **absence** of **abnormal CSF** findings

Lozier et al (2006)





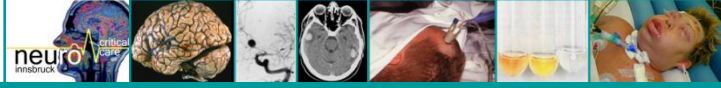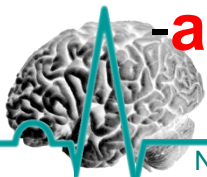
## NEUROCRITICAL CARE COMPLICATIONS IN THE ICU

Catheter **colonization** is defined by at least **two positive CSF cultures** with **expected CSF** profiles and **lack** of clinical signs.

**Pathological CSF** findings in the **absence** of **positive** cultures characterizes a **suspected** device-related **infection**, whereas **definite** nosocomial meningitis or ventriculitis is defined by:

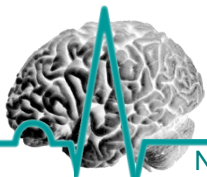

- **positive CSF culture** accompanied by
- **abnormal CSF findings** or
- **appropriate clinical signs and symptoms.**

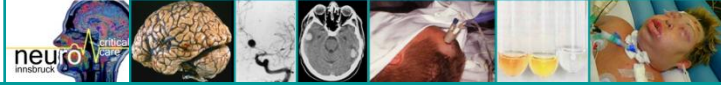




## NEUROCRITICAL CARE COMPLICATIONS IN THE ICU

In addition, **‘aseptic’ inflammation** resulting from tissue response to tissue injury or stimulation by **non**infectious agents such as **blood breakdown products** or **chemicals** should be distinguished from infection.





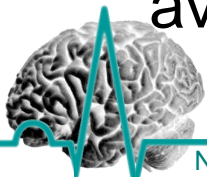## NEUROCRITICAL CARE COMPLICATIONS IN THE ICU

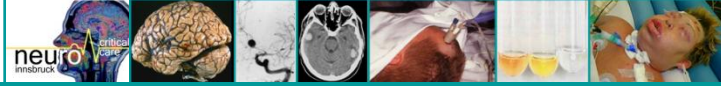
### Epidemiology, pathogenesis, and microbiology

The true prevalence of healthcare-associated intracranial infectious complications is difficult to estimate because epidemiological data are limited.

Most reports refer to **postneurosurgical** (e.g., craniotomy and ventriculostomy) infectious complications.

In contrast, only few studies on the epidemiology of infections secondary to traumatic brain injury are available.

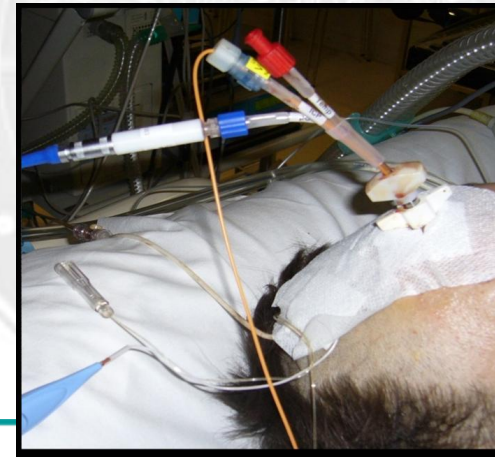
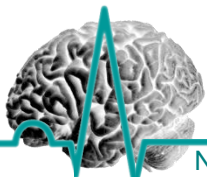


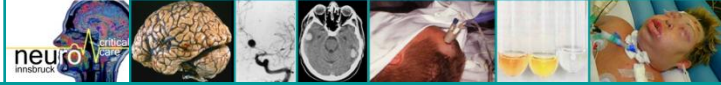


## NEUROCRITICAL CARE COMPLICATIONS IN THE ICU

Important **risk factors** for nosocomial intracranial infections are

- a history of neurosurgery,
- CSF leakage or
- recent head trauma,
- presence of cranial or extracranial infectious foci  
such as otitis, sinusitis or pneumonia and,
- potentially, an immunocompromised state.



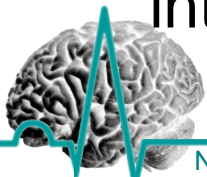

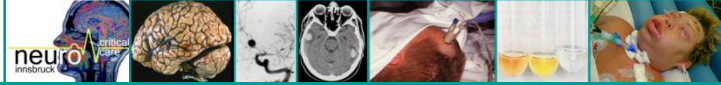
## NEUROCRITICAL CARE COMPLICATIONS IN THE ICU

Incidence of **ventriculostomy**-related infections: **2 to 27%**.

A recent meta-analysis of 23 retrospective studies reported a cumulative rate of positive CSF cultures of **8,8% per patient** and **8.1% per external ventricular drainage (EVD)**. (Lozier, 2002)

It has been claimed that the majority of EVD-related infections occurs within the **first week** after insertion, but recent studies identified a later peak of infection **even after 2 weeks**, particularly in patients with **prolonged** EVD placement due to severe intracranial disease. (van Zanten, 2005, Lackner , 2008)





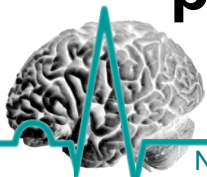## NEUROCRITICAL CARE COMPLICATIONS IN THE ICU

As infection may be acquired by introduction of bacteria following insertion of a new catheter, **routine exchange of catheters** might be actually **harmful** by possibly increasing the rates of infection (Lo, 2002).

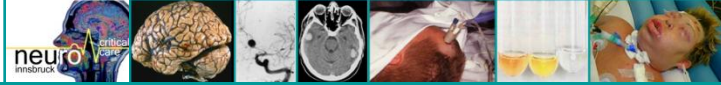
Other **relevant risk factors** for EVD-related intracranial infection are

- frequency of CSF sampling,**
- intraventricular hemorrhage,**
- surgical technique, and**
- presence of other distant infections.**

(Korinek, 2005)





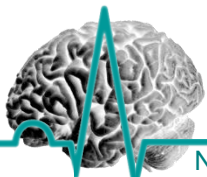


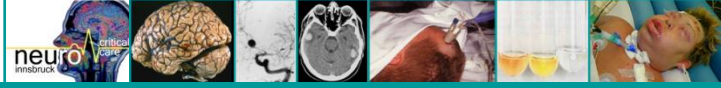
## NEUROCRITICAL CARE COMPLICATIONS IN THE ICU

The incidence of bacterial meningitis after moderate or severe **traumatic brain injury** has been estimated to range between 1 and 2% with **CSF leakage** as the major risk factor and **fracture of the basal** skull increasing the risk up to **25%**.

Approximately, 1,5% of patients suffer from postcraniotomy nosocomial meningitis as a serious complication.

(Weisfelt, 2007)





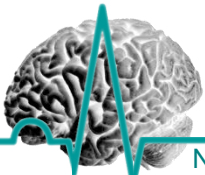
## NEUROCRITICAL CARE COMPLICATIONS IN THE ICU

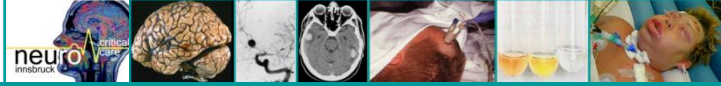
Underlying conditions such as a **history of neurosurgery** or **CSF leakage** are seen in **94%** of the episodes,

**28%** of the patients have more than one risk factor.

**Any kind of neurosurgical intervention** accounts for **64%** of the infections, whereas an **immuno-compromised** state is present in **28%** of the cohort, and **distant focus of infection** is identified in **18%**.

(Weisfelt, 2007)



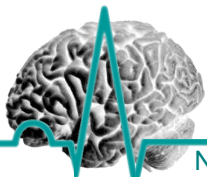


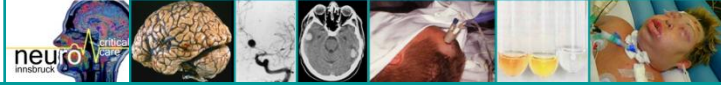
## NEUROCRITICAL CARE COMPLICATIONS IN THE ICU

**Staphylococci** have been incriminated to be the most important and most frequent causative agents **(up to 80%)**, whereas **Gram-negative bacilli** account for **10-15%**.

Anaerobes and fungi, primarily *Candida* species are rarely identified.

(Beer 2010)





## NEUROCRITICAL CARE COMPLICATIONS IN THE ICU

### Clinical features and diagnosis

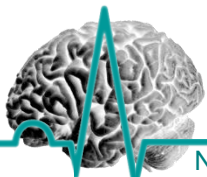
Any suspected intracranial infection must prompt an immediate diagnostic workup and the initiation of empirical antimicrobial chemotherapy.

**-Fever** and

-deterioration in the **level of consciousness** or

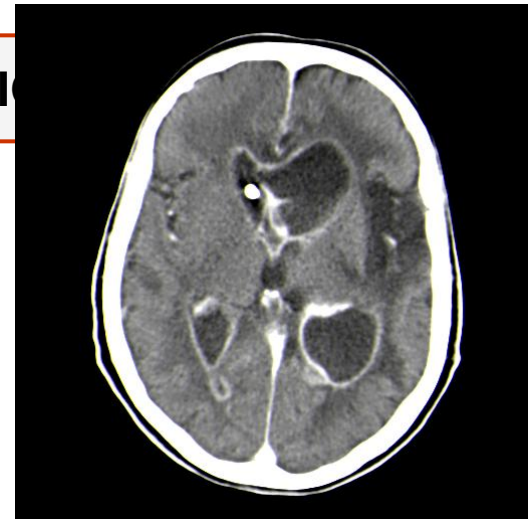
-an **increase in ICP** in the comatose or sedated patient

are important **early indicators** for the potential presence of **intracranial infections**.



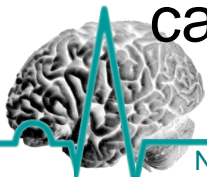## NEUROCRITICAL CARE COMPLICATIONS

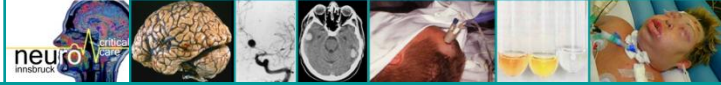
### Neuroimaging and CSF analysis



are the cornerstones in the diagnosis of CNS infections. It should be emphasized that performance of such examinations **must not delay** initiation of anti-infective therapy.

In many cases, **lumbar puncture** may be **contraindicated** due to increased intracranial pressure. CSF recovery may be possible through ventricular catheters.

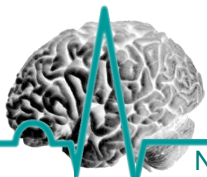


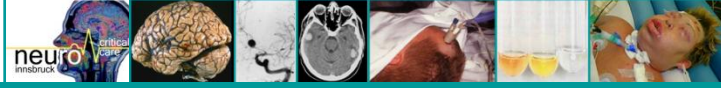


## NEUROCRITICAL CARE COMPLICATIONS IN THE ICU

Analysis of **ventricular CSF** does **not** always allow the diagnosis of bacterial meningitis, as **CSF circulation** and thereby spread of the infection might **be blocked** with blood or expanding masses.

The presence of a **focal collection of pus** (e.g., abscess, empyema) warrants immediate **neurosurgical evacuation** both to reduce ICP and to allow for microbiological analysis of the purulent collection.





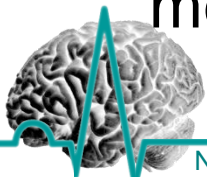
## NEUROCRITICAL CARE COMPLICATIONS IN THE ICU

In addition, **cultures** from **blood** and other **body fluids** such as secretions from paranasal sinus must be obtained.

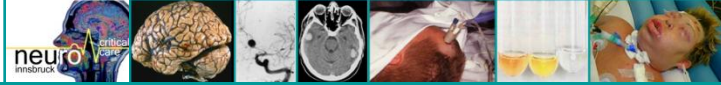
However, cultures may require prolonged incubation times and the result may be negative in patients with prior antibiotic therapy.

Comparing the results from **Gramstains** and **CSF cultures** : Gram staining has a very **high specificity** but an un-acceptably **low sensitivity** (18%) in **screening** for **device-related** bacterial meningitis.

Schade 2006



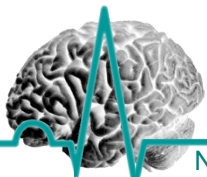


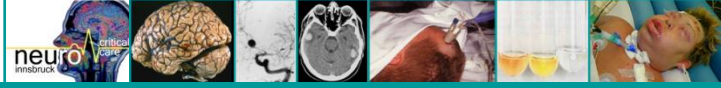


## NEUROCRITICAL CARE COMPLICATIONS IN THE ICU

In every patient with a history of neurosurgery or head trauma, there must be a high level of suspicion for intracranial infectious complications in case of the development of **systemic inflammatory response syndrome**.

On the contrary, clinical and biochemical parameters such as **fever** or increase in **acute-phase proteins** may also be a manifestation of the underlying neurological disease.





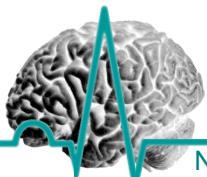
## NEUROCRITICAL CARE COMPLICATIONS IN THE ICU

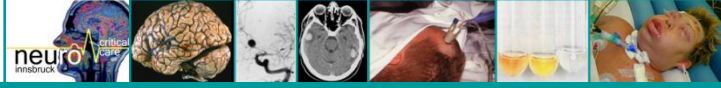
However, **monitoring of inflammatory parameters** does **not** allow discrimination between **systemic** or **intracranial** infection in the neuro-ICU patient population.

Studies investigating the value of **CSF biochemical parameters** such as

- CSF leukocyte count,
- CSF protein,
- increased CSF lactate, and
- decreased CSF/serum glucose ratio

conclude that **no single parameter** can reliably **predict or exclude** nosocomial intracranial infection.



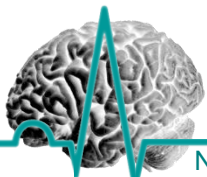


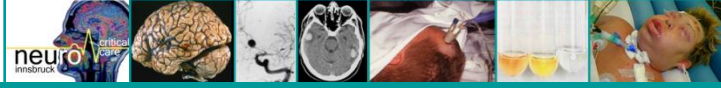
## NEUROCRITICAL CARE COMPLICATIONS IN THE ICU

Further, CSF analysis might be of limited value in identifying intracranial infections due to aseptic inflammation in case of **hemorrhagic** CSF.

In this setting, calculation of the **so-called cell index** (ratio of leukocytes and erythrocytes in CSF divided by the ratio of leukocytes and erythrocytes in peripheral blood) may **confirm** intracranial infection.

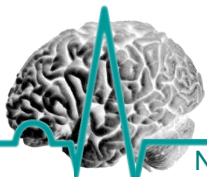
(Pfausler, 2004)

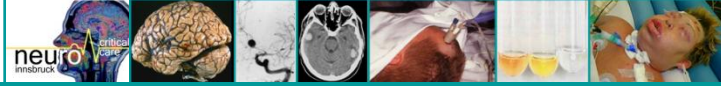




## NEUROCRITICAL CARE COMPLICATIONS IN THE ICU

A significant increase in the **cell index** preceded the diagnostic capacity by conventional means on average by 3 days.





## NEUROCRITICAL CARE COMPLICATIONS IN THE ICU

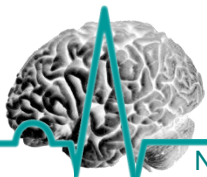

### Therapeutical considerations

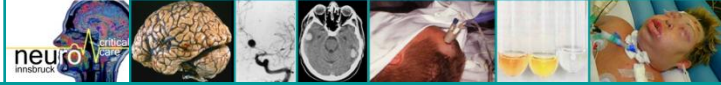
Delayed or inappropriate antimicrobial therapy is associated with

- increased morbidity and
- mortality

for many infectious diseases.

(Rasmussen 2008, Proulx 2006, Lala, 2005)



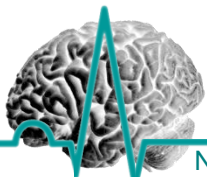


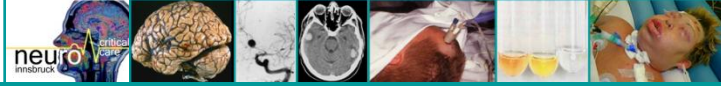
## NEUROCRITICAL CARE COMPLICATIONS IN THE ICU

### Therapeutical considerations

Risk factors for the administration of **inadequate anti-infective therapy** are

- preceding antibiotic therapy during the same hospitalization,
- longer duration of indwelling catheterization, and
- infections caused by multidrug resistant bacteria and infections by *Candida* species. (Iregui, 2002)

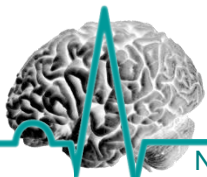




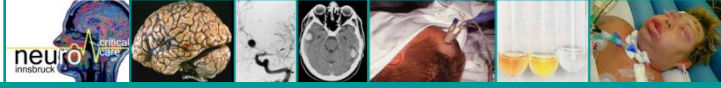
## NEUROCRITICAL CARE COMPLICATIONS IN THE ICU

Empirical antimicrobial therapy of nosocomial intracranial infections must consider the

- most likely pathogens** involved,
- local **resistance** pattern,
- underlying disease, and
- patient factors such as  
age,  
comorbidities, and  
immune status.

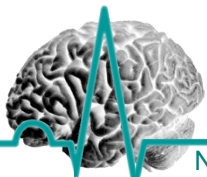


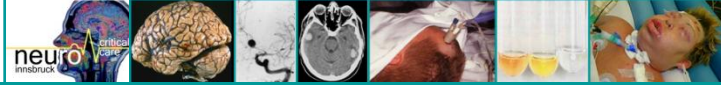




## NEUROCRITICAL CARE COMPLICATIONS IN THE ICU

The antibiotics selected must adequately **penetrate** the **blood–brain** and **blood–CSF barriers**





## NEUROCRITICAL CARE COMPLICATIONS IN THE ICU

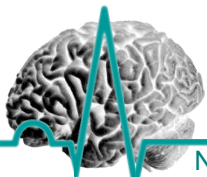
**Table 1 Recommendations for empiric antimicrobial therapy for bacterial intracranial infections in adults according to risk factor**

Risk factor	Common pathogens	Preferred antimicrobial therapy <sup>a</sup>
Post craniotomy	Staphylococci (e.g., <i>S. aureus</i> , <i>S. epidermidis</i> ), Gram-negative bacilli	Vancomycin or linezolid plus third <sup>b</sup> (or fourth <sup>c</sup> ) generation cephalosporin
Penetrating head injury	Staphylococci (e.g. <i>S. aureus</i> , <i>S. epidermidis</i> ), Gram-negative bacilli	Vancomycin or linezolid plus third <sup>b</sup> (or fourth <sup>c</sup> ) generation cephalosporin
Basal skull fracture (early)	<i>Streptococcus pneumoniae</i> , hemolytic streptococci, anaerobes (i.e., microbial oral flora)	Third <sup>b</sup> generation cephalosporin plus vancomycin or linezolid (plus metronidazol)

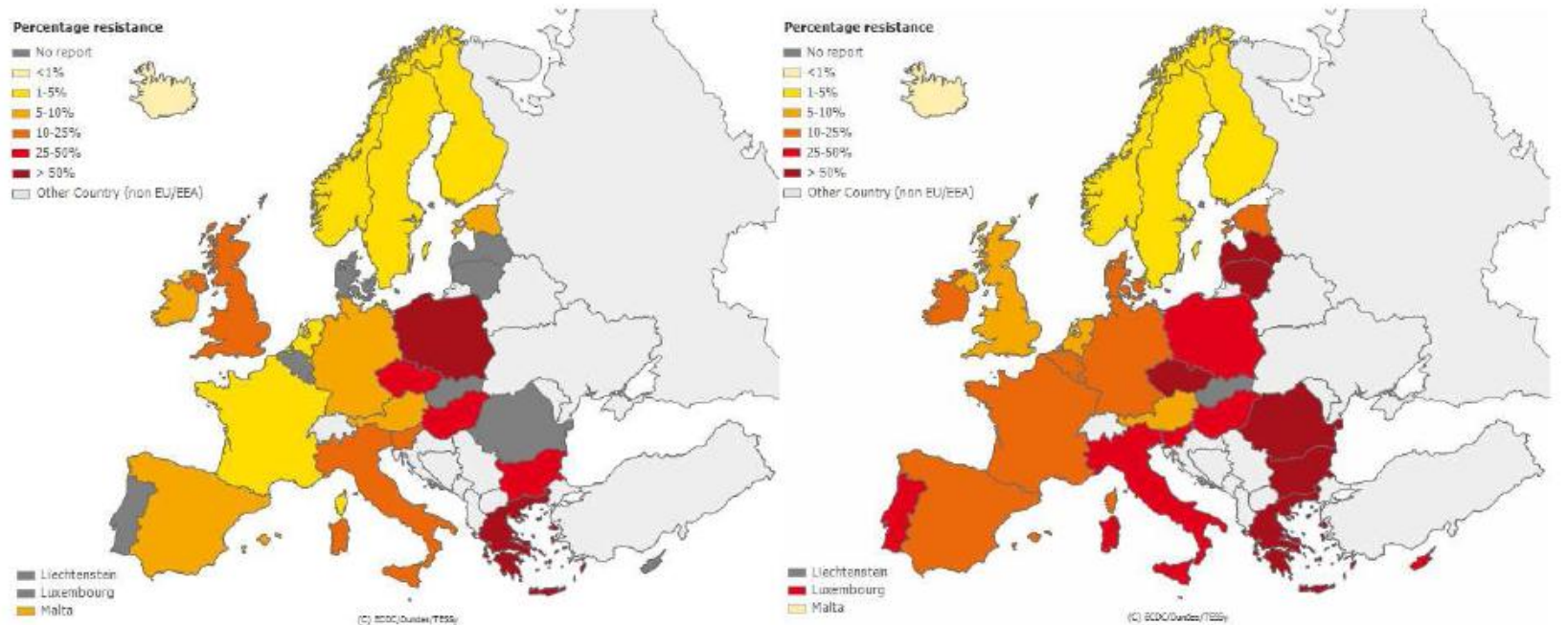
<sup>a</sup> Suggested daily dosing in adult patients with normal renal and/or hepatic function: vancomycin 15 mg/kg every 8 h to maintain a serum trough concentration of 15–20 g/l; linezolid 600 mg every 12 h; meropenem 2 g every 8 h.

<sup>b</sup> Suggested daily dosing in adult patients with normal renal and/or hepatic function: cefotaxime 2 g every 4–6 h (antimicrobial coverage should be based on local antimicrobial susceptibility).

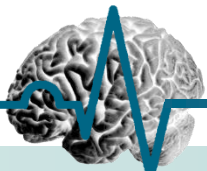<sup>c</sup> Suggested daily dosing in adult patients with normal renal and/or hepatic function: cefepime 2 g every 4–6 h (antimicrobial coverage should be based on local antimicrobial susceptibility).



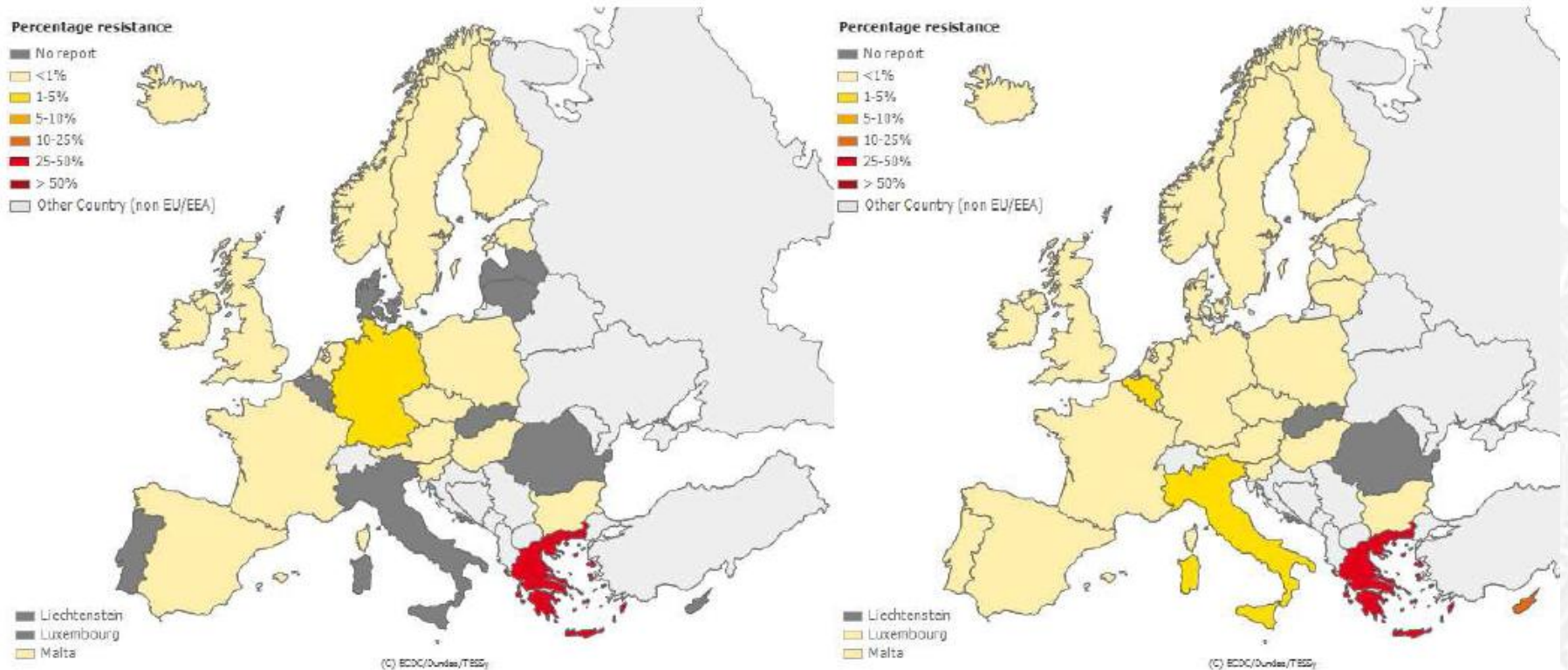
## Klebsiella pneumoniae - Resistance to 3<sup>rd</sup> cephalosporines 2005 vs 2011



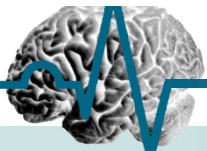EARS-net 02/2012



## Klebsiella pneumoniae - Resistance to carbapeneme 2005 vs 2011



EARs-net 02/2012





# Antibacterial antibiotics in nosocomial central nervous system infections

Gram-negative Erreger	Pseudomonas aeruginosa
Material	BK *
Antibiotikum	Imipenem
2005	<b>30%</b> (7/23)
2006	<b>47%</b> (8/17)
2007	<b>50%</b> (9/18)
2008	<b>43%</b> (6/14)
2009	<b>35%</b> (7/20)
2010	<b>57%</b> (17/30)

P. aeruginosa (Trachealsekret, bronchoalveoläre Lavagen)	Isolate			Resistenz %
	Getestet	Sensibel	Resistent	
Imipenem	178	137	41	<b>23</b>
Ciprofloxacin	178	137	41	<b>23</b>
Ceftazidim	178	146	32	<b>18</b>
Gentamicin	178	151	27	<b>15,2</b>
Piperacillin/Tazobactam	178	163	15	<b>8,4</b>
4.Gen.Cephalosporin	178	159	19	<b>10,6</b>

*Resistance Report Medical University Innsbruck 2011  
C. Lass-Floerl, M. Fille 04/2012*



# Antibacterial antibiotics in nosocomial central nervous system infections

A 6020 Innsbruck

Fax : 50427442 ( )

geb. : 15.05.1970  
Krankenkasse : J  
Material : Liquor  
Eingangsdatum : 17.05.2011  
Entnahmedatum : 16.05.2011

## Teilbefund vom 19.05.2011

Untersuchungsauftrag : aerobe Kultur, Pilze, Langzeitbebrütung

Pilze : Befund folgt  
Liquor-Antibiotikaspiegel : Antibiotikaspiegel nachgewiesen

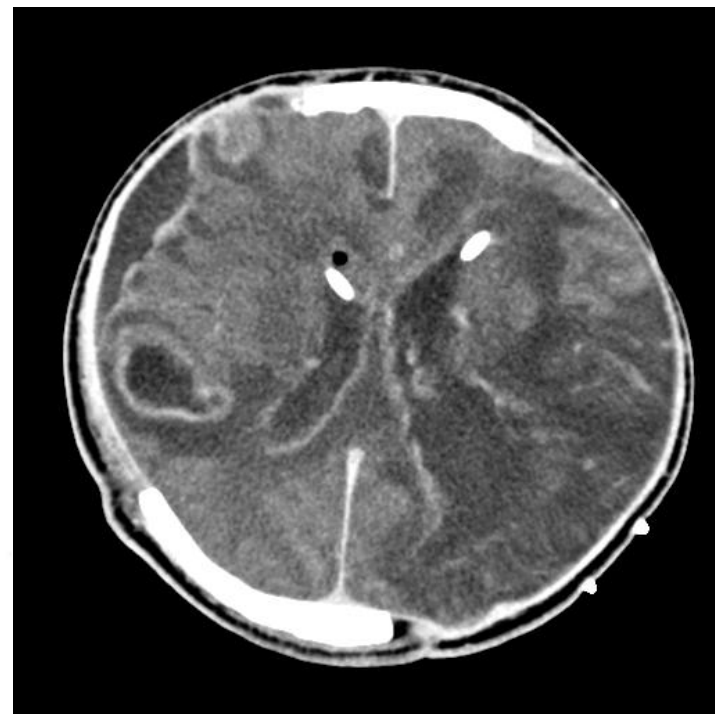
Kultur :

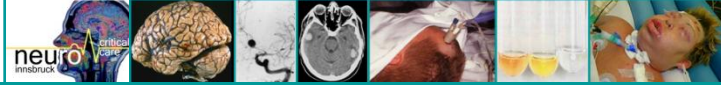
1. E.coli

Beta-Laktamasebildner mit breitem Wirkungsspektrum (ESBL)

Antibiotikum	Nr.	1
Penicillin G	1	R
Moxifloxacin	43	R
Azithromycin	44	R
Clindamycin	9	R
Cefazolin (c)	5	R
Tetracyclin	10	S
Trimethoprim + Sulfonamid	11	R
Aminopenicillin (d)	3	R
Gentamicin	17	R
Aminopen. + Clav. (e)	4	R
Cefuroxim - Axetil (f)	6	R
Cefuroxim (f)	22	R
Cefixim (g)	7	R
Cefoxitin (h)	23	S
Ciprofloxacin (i)	14	R
Piperac.-Tazobactam	39	S
Ceftriaxon (j)	25	R
Aztreonam	28	R
Cefotaxim	24	R
Imipenem	27	S
Ceftazidim (k)	26	R
Fosfomycin	31	S
Amikacin	19	S
Cefepim	37	R

S = sensibel, I = intermediär, R = resistent



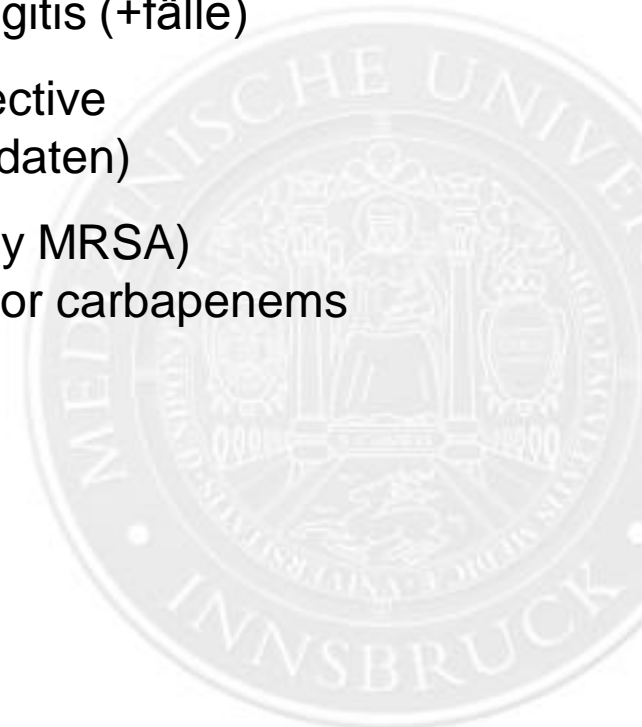
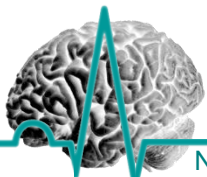


## NEUROCRITICAL CARE COMPLICATIONS IN THE ICU

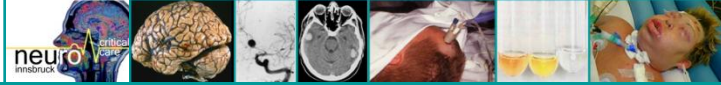
### Significance of the newer/alternative antibiotics in the therapy of nosocomial meningitis

- successfully treated single/small case series

- Daptomycin Gram-positive and negative, incl MRSA, MRSE, VRE  
single case reports in MRSA meningitis (+fälle)
- Linezolid only in Gram-positive spectrum effective  
excellent CSF penetration (unsere daten)
- Fosfomycin Gram-positive and negative (partially MRSA)  
only in combination with  $\beta$ -lactams or carbapenems  
excellent CSF penetration



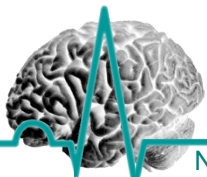




## NEUROCRITICAL CARE COMPLICATIONS IN THE ICU

### Significance of the newer/alternative antibiotics in the therapy of nosocomial meningitis (2)

- Aminoglycosides
  - limited penetration into CSF
  - „medicate high dosage, once a day and short“
  - measure of trough levels necessary (side-effects)
  - rescue therapy for gram-negative meningitis (especially enterococci and pseudomonas)
- Colistin
  - efficacious against Enterobacteriaceae (especially *P. aeruginosa*, *Acinetobacter baumannii*)
  - application only, if all other antibiotics are not susceptible to identified isolates**



# Infectious intracranial complications in the neuro-ICU patient population

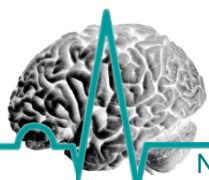
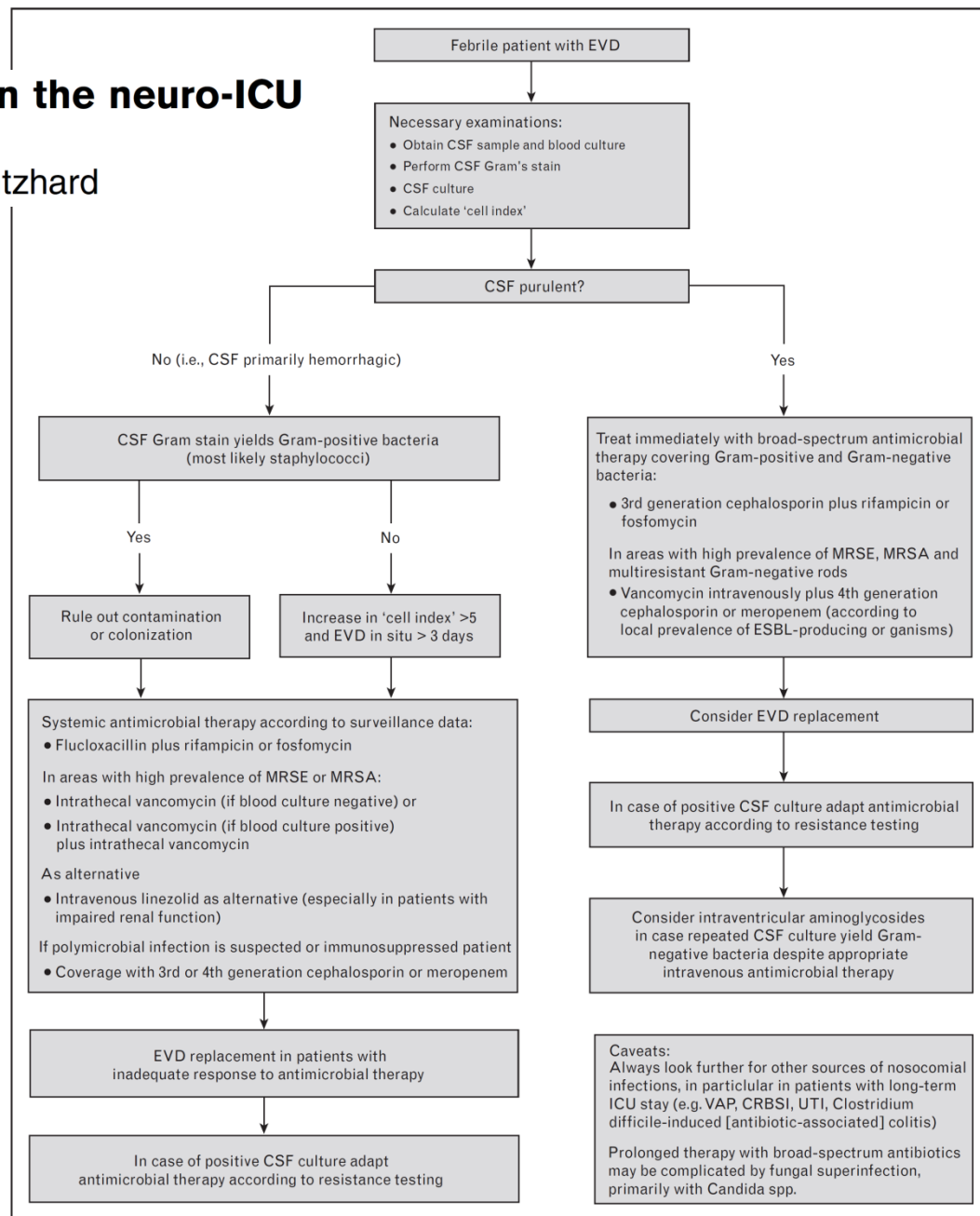
Ronny Beer, Bettina Pfausler and Erich Schmutzhard

Neurological Intensive Care Unit, Department of Neurology, Innsbruck Medical University, Innsbruck, Austria

Correspondence to Professor Erich Schmutzhard, MD, DTM&H (Liv.), Department of Neurology, Innsbruck Medical University, Anichstrasse 35, A-6020 Innsbruck, Austria

Tel: +43 512 504 23853; fax: +43 512 504 24243; e-mail: erich.schmutzhard@i-med.ac.at

**Current Opinion in Critical Care** 2010, 16:117–122



Febrile patient with EVD

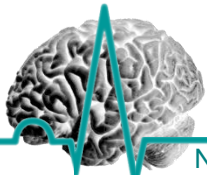
Necessary examinations:

- Obtain CSF sample and blood culture
- Perform CSF Gram's stain
- CSF culture
- Calculate 'cell index'

CSF purulent?

No (i.e., CSF primarily hemorrhagic)

Yes



No (i.e., CSF primarily hemorrhagic)

CSF Gram stain yields Gram-positive bacteria  
(most likely staphylococci)

Yes

No

Rule out contamination  
or colonization

Increase in 'cell index' >5  
and EVD in situ > 3 days

Systemic antimicrobial therapy according to surveillance data:

Yes

Treat immediately with broad-spectrum antimicrobial  
therapy covering Gram-positive and Gram-negative  
bacteria:

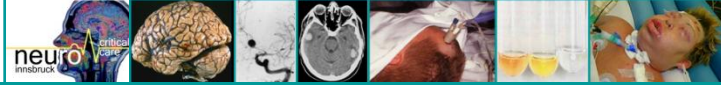
- 3rd generation cephalosporin plus rifampicin or fosfomycin

In areas with high prevalence of MRSE, MRSA and  
multiresistant Gram-negative rods

- Vancomycin intravenously plus 4th generation  
cephalosporin or meropenem (according to  
local prevalence of ESBL-producing organisms)

Consider EVD replacement





Systemic antimicrobial therapy according to surveillance data:

- Flucloxacillin plus rifampicin or fosfomycin

In areas with high prevalence of MRSE or MRSA:

- Intrathecal vancomycin (if blood culture negative) or
- Intrathecal vancomycin (if blood culture positive) plus intrathecal vancomycin

As alternative

- Intravenous linezolid as alternative (especially in patients with impaired renal function)

If polymicrobial infection is suspected or immunosuppressed patient

- Coverage with 3rd or 4th generation cephalosporin or meropenem

EVD replacement in patients with inadequate response to antimicrobial therapy

In case of positive CSF culture adapt antimicrobial therapy according to resistance testing

Consider EVD replacement

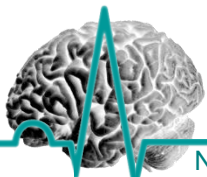
In case of positive CSF culture adapt antimicrobial therapy according to resistance testing

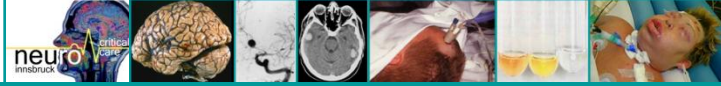
Consider intraventricular aminoglycosides in case repeated CSF culture yield Gram-negative bacteria despite appropriate intravenous antimicrobial therapy

Caveats:

Always look further for other sources of nosocomial infections, in particular in patients with long-term ICU stay (e.g. VAP, CRBSI, UTI, Clostridium difficile-induced [antibiotic-associated] colitis)

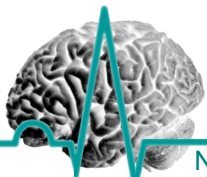
Prolonged therapy with broad-spectrum antibiotics may be complicated by fungal superinfection, primarily with Candida spp.

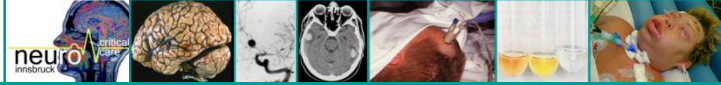




## NEUROCRITICAL CARE COMPLICATIONS IN THE ICU

As in the neuro-ICU-patient population nosocomial intracranial infections can be caused by **multidrug** resistant Gram-**positive** and Gram-**negative** pathogens, initial empiric treatment with the glycopeptide antibiotic **Vancomycin** in combination with a **Cephalosporin** with antipseudomonal activity or a **Carbapenem** is recommended until culture results provide information to adapt antimicrobial therapy according to **resistance testing**.

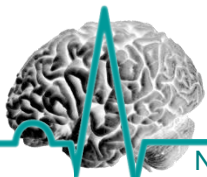




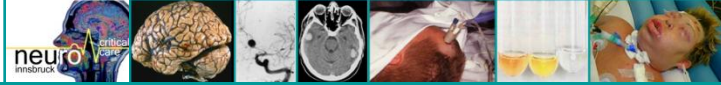
## NEUROCRITICAL CARE COMPLICATIONS IN THE ICU

In patients with a contraindication for systemic vancomycin administration in whom a ventricular catheter is placed, **vancomycin** can be safely administered **intrathecally**. (Pfausler, 2003)

For patients with severe allergy to betalactam antibiotics, moxifloxacin might prove as an alternative. (Beer 2012)





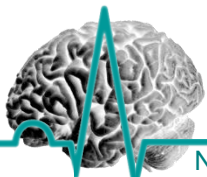


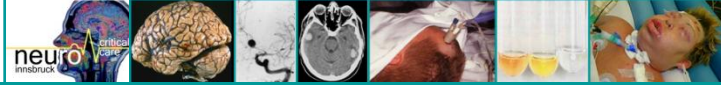
## NEUROCRITICAL CARE COMPLICATIONS IN THE ICU

The efficacy of **linezolid** for the treatment of nosocomial Gram-positive ventriculo-meningitis has been demonstrated recently (Beer 2007).

Nosocomial intracranial infections due to antibiotic resistant *Acinetobacter* species is becoming an increasingly clinical entity.

In these cases, combination therapy of systemic and intrathecally administered **polymyxins** plus removal of infected devices is recommended.



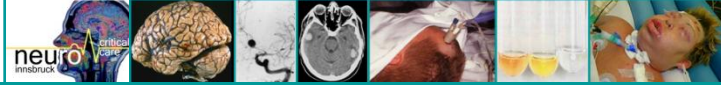


## NEUROCRITICAL CARE COMPLICATIONS IN THE ICU

Recommendations on the **duration** of antimicrobial therapy of infectious intracranial complications in the neuro-ICU population have not been studied rigorously. Mostly, treatment is continued for 10–14 days. If repeated CSF cultures are negative, some experts have suggested shorter durations.

However, it needs to be stressed that therapy of nosocomial intracranial infectious complications therapy must be individualized because some patients with preceding or concurrent anti-infective therapy may need appropriate empiric antimicrobial treatment despite negative microbiological testing.





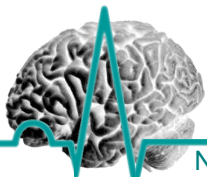
## NEUROCRITICAL CARE COMPLICATIONS IN THE ICU

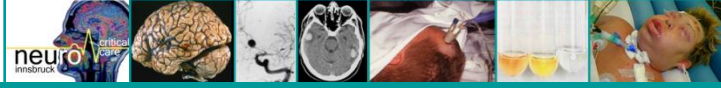
Although the routine prophylactic exchange of non infected indwelling devices is still discussed controversially, consensus exists on the **timely removal of neurosurgical hardware** infected with pathogens capable of biofilm formation.

Importantly, catheter removal requires **concomitant antimicrobial** therapy.

Recurrence of nosocomial infections is reported in 25% of cases.

Therefore, a high level of suspicion needs to be maintained after termination of antimicrobial therapy.



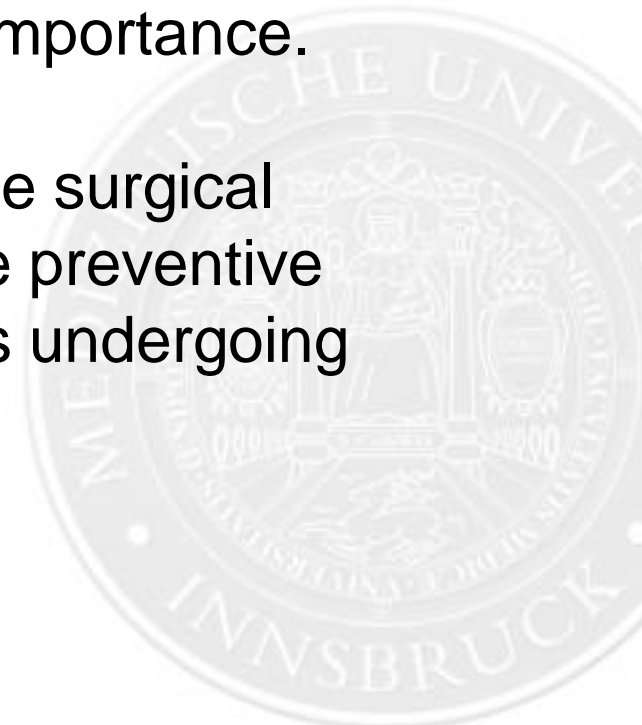
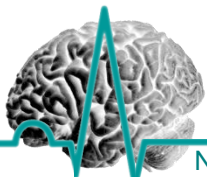


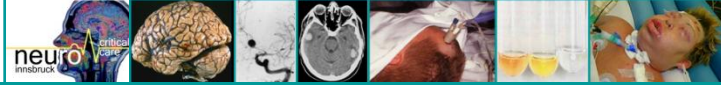
## NEUROCRITICAL CARE COMPLICATIONS IN THE ICU

### Prevention

Because of difficulties in early diagnosis and subsequent delayed initiation of appropriate antimicrobial therapy, prevention of nosocomial intracranial infection is of paramount importance.

Preventive measures include adequate surgical techniques and hygiene as well as the preventive administration of antibiotics in patients undergoing neurosurgery.



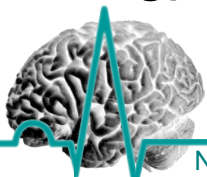

## NEUROCRITICAL CARE COMPLICATIONS IN THE ICU

However, the possible induction of antimicrobial resistance, leading to major healthcare problems, is a significant concern.

A relatively new option that may overcome this disadvantage is the introduction of ventriculostomy catheters impregnated with **silver nano-particles**. (Lackner, 2008)

A prospective pilot study and a retrospective analysis found reduced infection rates with the use of silver nano-particles bearing EVD catheters.



## NEUROCRITICAL CARE COMPLICATIONS IN THE ICU

### Prevention

strict surgical protocols ( e.g. hair clipping not shaving)

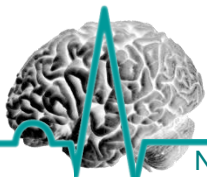
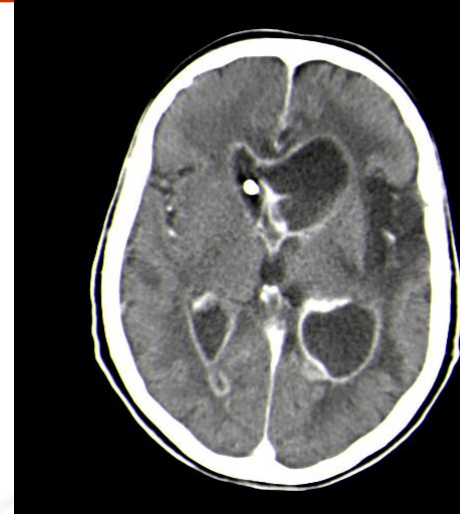minimizing blood loss and tissue trauma

avoidance of CSF leakage

use of double layer of gloves when handling implantable devices

### Extra-ventricular drains

- percutaneous tunneling of the catheters for at least 5 cm (*Sanders 2002*)
- strict hand hygiene for catheter handling
- antimicrobial-impregnated and silver-coated external ventricular (*Lackner 2008, Muttayah 2010, Adib 2011*)
- routine exchange of EVDs does not reduce the risk of infection (*Holloway 1996, Korinek 2006*)

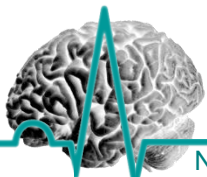
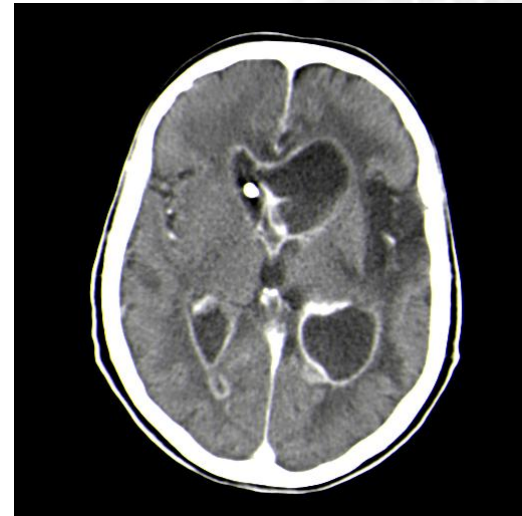



## NEUROCRITICAL CARE COMPLICATIONS IN THE ICU

**CONCLUSION:** Per-operative antibiotic prophylaxis, though clearly effective for the prevention of incision infections, does not prevent meningitis and tends to select prophylaxis resistant microorganisms.

*A.M. Korinek, 2006*



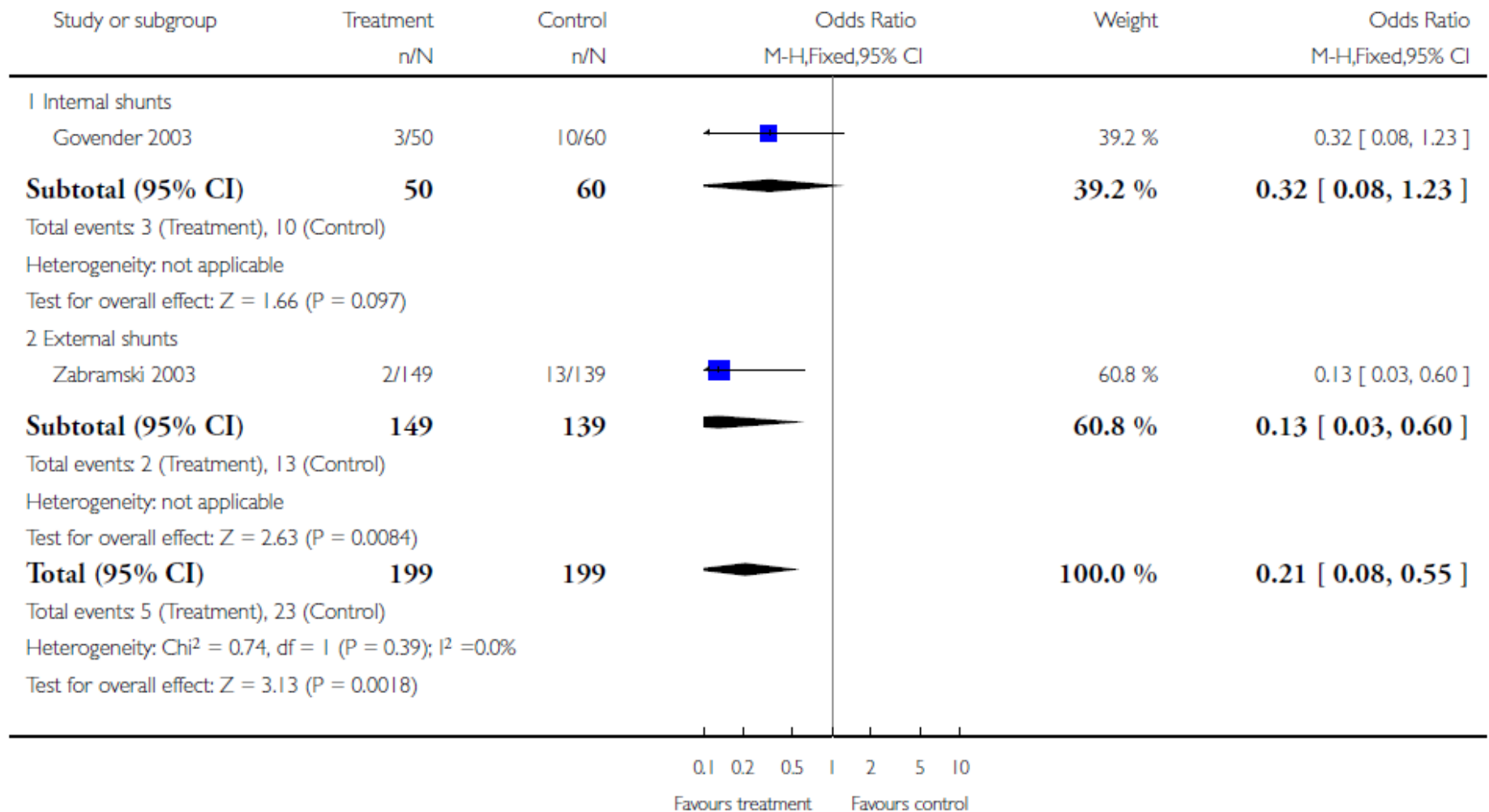


## Analysis 1.2. Comparison 1 Antibiotic-impregnated versus standard catheters, Outcome 2 Shunt infection.

Review: Antibiotic prophylaxis for surgical introduction of intracranial ventricular shunts

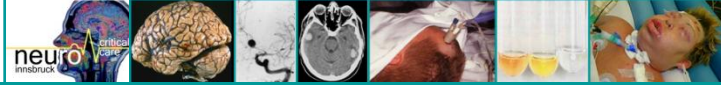
Comparison: 1 Antibiotic-impregnated versus standard catheters

Outcome: 2 Shunt infection



Cochrane, 2006

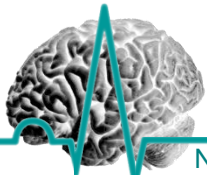




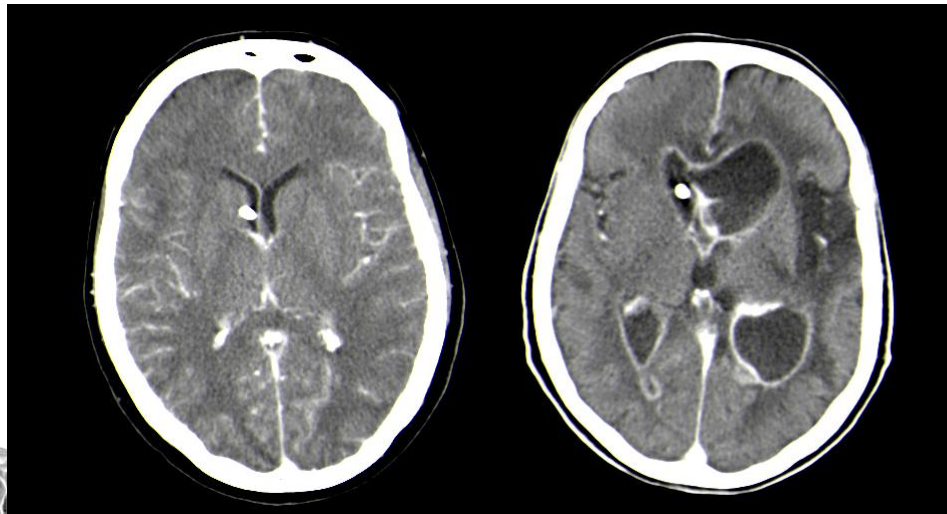
## NEUROCRITICAL CARE COMPLICATIONS IN THE ICU

### Conclusion

- Nosocomial central nervous system infections are rather rare
- Clinical signs and symptoms as well as CSF findings are often hampered by concomitant neurological disease and altered CSF findings post neurosurgical procedures
- Guidelines conforming antibiotic therapy is efficacious in most cases
- Increasing numbers of multi-drug resistant microbes require an increasing alertness to adequate and alternative therapy(-ies)
- Intrathecal application of antibiotics could be an efficacious therapy in selected cases, especially, of ventriculitis
- Prophylactic procedures are able to reduce infection rate



# THANK YOU FOR YOUR ATTENTION



A 6020 Innsbruck

Fax : 50424288 ( )

Krankenkasse : N  
 Material : Abstrich Nase  
 Eingangsdatum : 21.02.2007  
 Entnahmedatum : 20.02.2007

Endbefund vom 24.02.2007

Lfd.

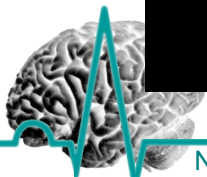
Untersuchungsauftrag : A-aerobe Kultur

Kultur :

1. Pseudomonas aeruginosa
2. Enterococcus sp.
3. Morganella morganii

Antibiotikum	Nr.	1	2	3
Penicillin G	1	R	R	R
Isoxazolylpenicill.(a)	2	R	R	R
Azithromycin		R	R	R
Clindamycin	9	R	R	R
Cefazolin (c)	5	R	R	R
Tetracyclin	10	R	R	R
Trimethoprim + Sulfonamid	11	R	R	R
Aminopenicillin (d)	3	R	S	R
Gentamicin	17	S	R	R
Aminopen. + Clav. (e)	4	R	S	R
Cefuroxim - Axetil (f)	6	R	R	R
Cefuroxim (f)	22	R	R	R
Cefixim (g)	7	R	R	R
Cefoxitin (h)	23	R	R	S
Ciprofloxacin (i)	14	S	S	R
Piperac.-Tazobactam	39	R	S	S
Ceftriaxon (i)	25	R	R	R
Aztreonam	28	S		S
Cefotaxim	24	R	R	R
Imipenem	27	R	S	S
Ceftazidim (k)	26	S		R
Fosfomycin	31	R	S	R
Amikacin	19	S	R	S
Vancomycin	33		S	
Rifampicin	32		S	
Fusidinsäure	34		S	
Cefepim	37	S	R	S

S = sensibel, I = intermediär, R = resistent



# THANK YOU FOR YOUR ATTENTION

## AND MANY THANKS TO ALL MY COWORKERS OF THE NICU INNSBRUCK, AUSTRIA

BETTINA PFAUSLER, RONNY BEER, RAIMUND HELBOK,  
GREGOR BROESSNER, PETER LACKNER, STEPHANIE KLIEN,  
MARLENE FISCHER, ANELIA DIETMANN

A 6020 Innsbruck

Krankenkasse : N  
Material : Abstrich Nase  
Eingangsdatum : 21.02.2007  
Entnahmedatum : 20.02.2007

Fax : 50424288 ( )

Endbefund vom 24.02.2007

Lfd.

Untersuchungsauftrag : A-aerobe Kultur

Kultur :

1. Pseudomonas aeruginosa
2. Enterococcus sp.
3. Morganella morganii

Antibiotikum	Nr.	1	2	3
Penicillin G	1	R	R	R
Isoxazolylpenicill.(a)	2	R	R	R
Azithromycin		R	R	R
Clindamycin	9	R	R	R
Cefazolin (c)	5	R	R	R
Tetracyclin	10	R	R	R
Trimethoprim + Sulfonamid	11	R	R	R
Aminopenicillin (d)	3	R	S	R
Gentamicin	17	S	R	R
Aminopen. + Clav. (e)	4	R	S	R
Cefuroxim - Axetil (f)	6	R	R	R
Cefuroxim (f)	22	R	R	R
Cefixim (g)	7	R	R	R
Cefoxitin (h)	23	R	R	S
Ciprofloxacin (i)	14	S	S	R
Piperac.-Tazobactam	39	R	S	S
Ceftriaxon (i)	25	R	R	R
Aztreonam	28	S		S
Cefotaxim	24	R	R	R
Imipenem	27	R	S	S
Ceftazidim (k)	26	S		R
Fosfomycin	31	R	S	R
Amikacin	19	S	R	S
Vancomycin	33		S	
Rifampicin	32		S	
Fusidinsäure	34		S	
Cefepim	37	S	R	S

S = sensibel, I = intermediär, R = resistent

